

CONTINUOUS RUNNING SUTURING VERSUS SUBCUTICULAR SUTURING TECHNIQUES IN UPPER BLEPHAROPLASTY

Ari Hasan Rashid ^a, Ari Raheem Qader ^b, Hawree Abdulsattar Hasan ^c, and Faraydoon Karim Rasul ^c



Submitted: 17/9/2019; Accepted: 1/12/2020; Published: 21/12/2020

ABSTRACT

Background

Upper blepharoplasty is among the most common procedures performed by plastic surgeons. In this procedure upper eyelid excess skin, muscle, and fat are removed and the wound is closed by a variety of methods.

Objectives

To evaluate the differences in the complications and the outcomes of the different methods of skin closure following upper eyelid blepharoplasty.

Patients and Methods

Standard upper blepharoplasty has been done for 38 patients which randomly selected into two groups, 20 patients to group A (continuous suturing technique) and 18 patients into group B (subcuticular technique).

Results

Assessment of the patients done after 5 days, 1 month, and 6 months post-operatively. Besides some minor complications of erythema and edema, there were only two patients, one in each group with moderate edema and ecchymosis. No other significant differences were found in terms of the complications between the two groups. Patient Observer Scar Assessment Scale used at 6 months post-operative. There was also no significant difference, the P-value of the patient scale was 0.23 and of the observer, the scale was 0.64.

Conclusion

In this study, we did not find a significant difference in the complications and the outcome between the aforementioned methods of eyelid wound closure. The selection of the procedure is up to the surgeon to select. We do not recommend the surgeons to change their method of closure. We provide our findings for consideration and further study.

Keywords: *Upper Blepharoplasty; Complications; Suture Material.*

^a Board Candidate at Kurdistan Board of Medical Specialties, Kurdistan Region, Iraq

^b Department of Surgery, College of Medicine, University of Sulaimani, Kurdistan Region, Iraq.

^c DOH, Kurdistan Region, Iraq.

Correspondence: arihrh@yahoo.com

INTRODUCTION

Upper blepharoplasty is among the most common procedures performed by plastic surgeons^(1,2). It is used to address the aging changes of the upper eyelid⁽³⁾. With aging, the skin of the upper eyelid becomes loose and hangs over the tarsus that results in the heaviness of the upper eyelid and may sometimes result in ptosis and interfere with the patients' vision^(1,4). There will be laxity of the orbital septum as well, as a result, the orbital fat pad will herniate⁽³⁾. In this procedure, the excess skin is removed, the position of the superior eyelid skin crease is corrected or recreated and excess lax muscle may be excised with or without removal of herniated orbital fat^(2,5). Closure of the wound can be done in a variety of methods using different suture materials, in which the review of the literature shows that it is dependent on the surgeons' preference to use a specific method of closure^(6,7).

Among these methods, two methods are commonly used for closure of the skin; those are non-absorbable continuous running suturing and non-absorbable continuous subcuticular suturing. However, there are differences in the outcome of the surgery with different closure techniques. The wound healing of the upper eyelid is excellent considering the skin character, and mostly the scar is less conspicuous than the other areas of the body and yet there might be the complications of the procedure like hematoma, chemosis, milia, lagophthalmus, asymmetry, ptosis, blindness and scarring⁽⁶⁻¹⁰⁾.

Most of the times our patients ask whether there will be a scar and how visible it will be and our surgeons use either one of the aforementioned methods of skin closure. The objective of our study is to evaluate the difference in the complications and the outcomes of the different methods of skin closure following upper eyelid blepharoplasty, therefore, we conducted a double-blind randomized clinical trial to identify the differences in the outcome of the upper blepharoplasty scar of the two aforementioned methods of skin closure. We also aim to identify the surgeons' comfort and duration of the procedures and patients' comfort level during suture removal.

PATIENTS AND METHODS

This is a double-blind randomized clinical trial conducted in Slemani Burn and Plastic Surgery Hospital between January 2018 and February 2019. 36 patients (all females) were selected in two groups. Selection into

the groups was randomized by flipping a coin, in which the heads were selected into the continuous suturing method groups (Group A) (20 patients), and the tails were selected into the subcuticular suturing method group (Group B) (18 patients). Patients were selected upon visiting the out-patient department of our hospital for upper blepharoplasty.

The patients were examined by the author and the procedures were explained to the patients in detail and all the patients have given the written consent to participate in this study. Inclusion criterion includes any patients who needed standard upper blepharoplasty without having any of the exclusion criteria which includes, history of poor scarring and wound healing problem, family history of hypertrophic scarring, thyroid eye disease, and any previous trauma or surgery in the eyelid. The patients and the observer were blinded and the Patient Observer Scar Assessment Scale (POSAS) is used to evaluate the outcome⁽¹¹⁾. The unpaired t-test is used to compare the results using SPSS V23.

Procedure

The procedure starts with the preoperative markings in the sitting position. The first marking starts with the inferior incision line which was drawn at (8-10 mm) above the eyelid margin at the mid-pupillary level, then extended medially and laterally following the curvature of the upper eyelid. It is extended medially as far as the level of the lacrimal punctum. Laterally it is extended to the crow's feet to camouflage the scar within the crow's feet, near the lateral canthus it should be higher than 5-7 mm from eyelid margin. Then the pinch technique is used to mark the upper incision line paying attention not to go any higher than 10 mm below the inferior margin of the eyebrow, and the line should be parallel to the inferior incision line, then it is tapered medially and laterally, Figure 1.

Local injection of Lidocaine 2% with adrenaline 1:80000 is injected, 1.5 – 2 ml per eyelid, then waiting for 15-20 mins for the local anesthetic to have an adequate effect. The skin is incised along the marking lines and a pair of tenotomy scissors are used to dissect between the skin and the muscle, then the skin is fully excised exposing the muscle underneath. The muscle is excised using scissors accordingly. Electrocautery used to provide adequate hemostasis. Fat removal is individualized according to the patients. Then three buried simple interrupted sutures using 6/0 Polyglycolic

Continuous Running Suturing Versus Subcuticular Suturing Techniques in Upper Blepharoplasty

acid suture on the round needle is used to approximate the muscle edges and dermis in the medial, middle and lateral parts of the wound, the same technique was used for both groups of the patients. For the skin closure, we used the same suture material which is 6/0 Polypropylene for both groups.

For group (A), a continuous running suturing with 1mm away from the wound edge and 2-3 mm apart

was performed. In group (B) horizontal subcuticular suturing was performed. After the closure of the skin, skin-tape is used for dressing. Stitch removal was done on the 5th post-operative day. The patients were seen again at 1 month and 6 months. At the 6th month post-operative period, POSAS was used to assess the outcome of the surgery, the patients were not informed about the type of suturing and the observer was also not aware of the type of suture used, Figure 2.

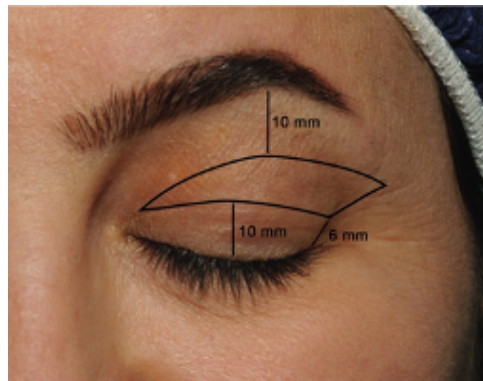

Figure 1. Pre-operative markings.

POSAS Patient name: _____
Date: _____ Visit No. []

Observer Scar Assessment Scale :

	Normal skin	1	2	3	4	5	6	7	8	9	10	worst scar imaginable
Vascularity		<input type="radio"/>	<input type="radio"/>	<input type="radio"/>	<input type="radio"/>	<input type="radio"/>	<input type="radio"/>	<input type="radio"/>	<input type="radio"/>	<input type="radio"/>	<input type="radio"/>	
Pigmentation		<input type="radio"/>	<input type="radio"/>	<input type="radio"/>	<input type="radio"/>	<input type="radio"/>	<input type="radio"/>	<input type="radio"/>	<input type="radio"/>	<input type="radio"/>	<input type="radio"/>	
Thickness		<input type="radio"/>	<input type="radio"/>	<input type="radio"/>	<input type="radio"/>	<input type="radio"/>	<input type="radio"/>	<input type="radio"/>	<input type="radio"/>	<input type="radio"/>	<input type="radio"/>	
Relief		<input type="radio"/>	<input type="radio"/>	<input type="radio"/>	<input type="radio"/>	<input type="radio"/>	<input type="radio"/>	<input type="radio"/>	<input type="radio"/>	<input type="radio"/>	<input type="radio"/>	
Pliability		<input type="radio"/>	<input type="radio"/>	<input type="radio"/>	<input type="radio"/>	<input type="radio"/>	<input type="radio"/>	<input type="radio"/>	<input type="radio"/>	<input type="radio"/>	<input type="radio"/>	

Total Score: _____

Patient Scar Assessment Scale:

	No, no complaint	1	2	3	4	5	6	7	8	9	10	Yes, worst imaginable
Is the scar painful ? (آلوتنه‌گه‌ن نازار مهه)		<input type="radio"/>	<input type="radio"/>	<input type="radio"/>	<input type="radio"/>	<input type="radio"/>	<input type="radio"/>	<input type="radio"/>	<input type="radio"/>	<input type="radio"/>	<input type="radio"/>	
Is the scar itching? (آلوتنه‌گه‌ن خورانی مهه)		<input type="radio"/>	<input type="radio"/>	<input type="radio"/>	<input type="radio"/>	<input type="radio"/>	<input type="radio"/>	<input type="radio"/>	<input type="radio"/>	<input type="radio"/>	<input type="radio"/>	
Is the color of the scar different? (آلوتنه‌گه‌ن شوتنه‌گه‌ن جهولان)		<input type="radio"/>	<input type="radio"/>	<input type="radio"/>	<input type="radio"/>	<input type="radio"/>	<input type="radio"/>	<input type="radio"/>	<input type="radio"/>	<input type="radio"/>	<input type="radio"/>	
Is the scar more stiff? (آلوتنه‌گه‌ن رده)		<input type="radio"/>	<input type="radio"/>	<input type="radio"/>	<input type="radio"/>	<input type="radio"/>	<input type="radio"/>	<input type="radio"/>	<input type="radio"/>	<input type="radio"/>	<input type="radio"/>	
Is the thickness different ? (آلوتنه‌گه‌ن جهولان مهه)		<input type="radio"/>	<input type="radio"/>	<input type="radio"/>	<input type="radio"/>	<input type="radio"/>	<input type="radio"/>	<input type="radio"/>	<input type="radio"/>	<input type="radio"/>	<input type="radio"/>	
Is the scar irregular? (هه‌ج نایزگیه‌گ مهه نه آلوتنه‌گه‌ن)		<input type="radio"/>	<input type="radio"/>	<input type="radio"/>	<input type="radio"/>	<input type="radio"/>	<input type="radio"/>	<input type="radio"/>	<input type="radio"/>	<input type="radio"/>	<input type="radio"/>	

Total score: _____

Figure 2. POSAS Scale.

RESULTS

Over 13 months, 38 patients were operated on, age ranging between 32 to 60 years, all were females. Twenty patients were selected into group A with the mean age of 45 years and eighteen patients were selected into group B with the mean age of 45 years. Assessment was done after five days and after one month. The final assessment was done at 6 months (\pm 18 days) postoperatively.

Besides minor complications such as erythema and edema that were noted in 5 patients of group A and 4 patients of group B, only one patient of the group (A) had moderate to severe edema and ecchymosis, which completely resolved in three weeks time. One patient from the group (B) also had moderate edema

and ecchymosis resolved completely in two weeks.

No suture marks were noted in all patients and no ptosis or lagophthalmus, Table 1.

Regarding the comparison of the groups in terms of patient scar assessment scale, there was no significant difference (p-value: 0.23). In terms of observer assessment scale, there was no significant difference (p-value: 0.64). In terms of milia, there was no significant difference (p-value: 0.55). In terms of pain during suture removal, there was also no significant difference (p-value: 0.13), Figure 3,4. However, the surgeons were more comfortable performing the continuous suturing technique and it took about 70% of the time required to perform the subcuticular suturing, (p-value: 0.00).

Table 1. Complications (*Edema and Erythema, **In minutes).

Groups	Milia	Mild E/E*	Moderate E/E*	Pain	Lagophthalmus	Suture marks	Time**	Patient scale	Observer Scale
Continuous	2	5	1	2.47	0	0	6.67	8.33	7.1
Subcuticular	3	4	1	2.83	0	0	9.55	8.42	7.17
p-value	0.55	0.96		0.13			0.00	0.23	0.64

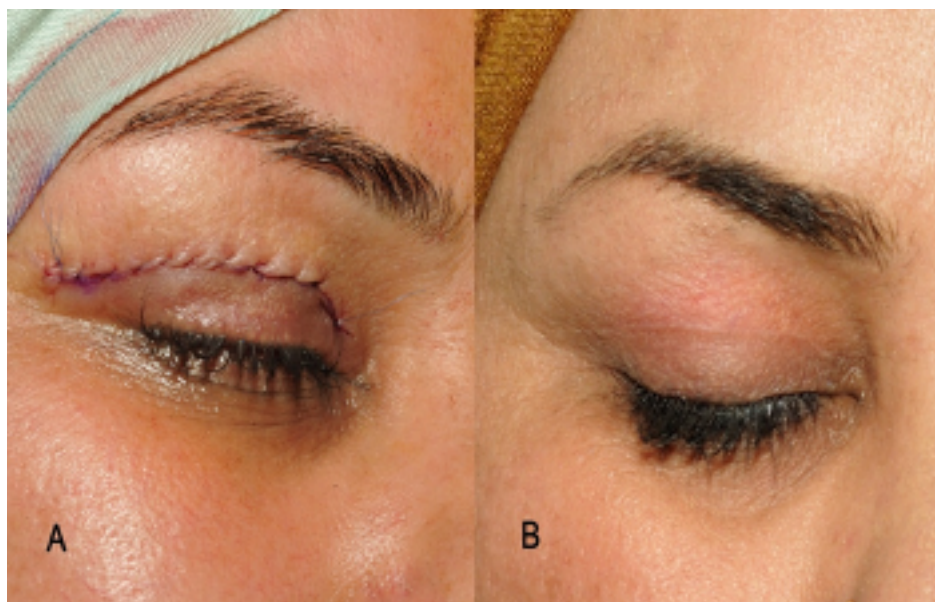


Figure 3. Continuous Suturing. A: Intra-Op. B: 6 Months Post-Op.

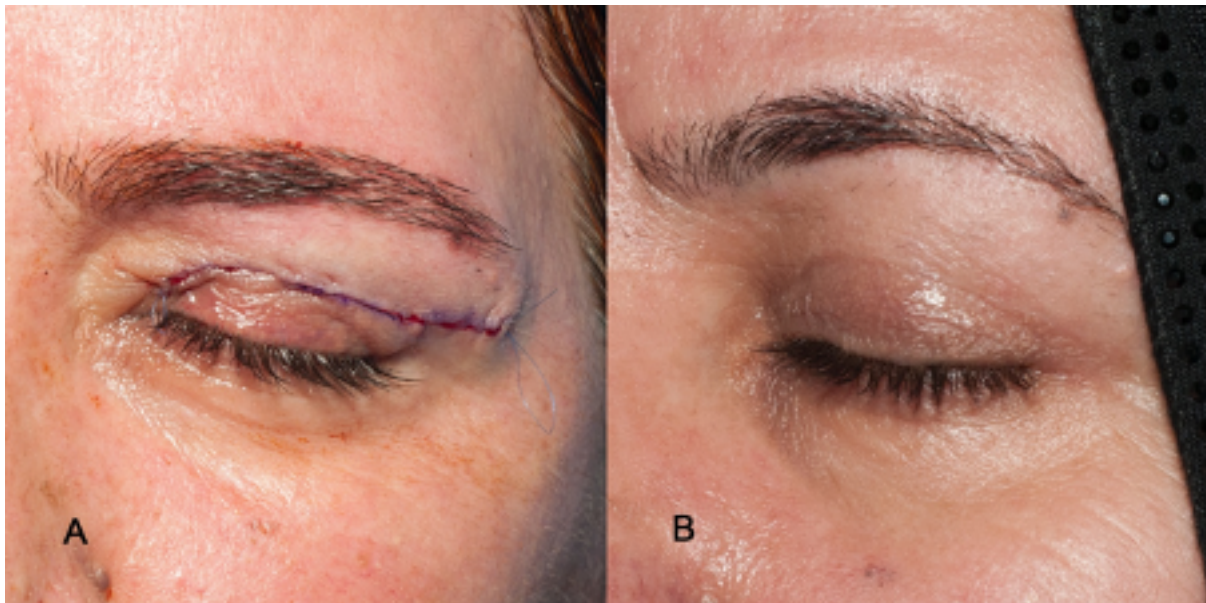

Figure 4. Subcuticular suturing. A: Intra-Op. B: 6 Months Post-Op.

DISCUSSION

Blepharoplasty is a surgical procedure that creates a wound in the upper eyelid that requires closure. There are many methods of the closure of the wound, either using absorbable or non-absorbable sutures, with the different suture materials and different techniques or not using a suture material at all (using cyanoacrylate)⁽⁶⁾.

We have reviewed some studies conducted on the upper blepharoplasty, there was not much focus on the suturing techniques as different surgeons use different methods^(3-5,12-14). In our center, the surgeons mostly perform subcuticular and continuous suturing techniques using non-absorbable suture materials like polypropylene. We conducted this study to identify any difference between these two techniques. We have found that the outcome of the scar showing no significant difference between the two techniques.

We have compared the patient scar assessment scale of the two groups and found no statistically significant difference, so as with the observer scar assessment scale. Previous studies about blepharoplasty suturing techniques are quite a few, and they have found that there are not quite differences between different techniques⁽¹²⁾.

Comparing our study to the study conducted by Joshi et. al., they have found the difference in the development

of more milia in continuous technique with no other statistically significant difference between the two groups⁽⁶⁾. Previous studies did not use a scar assessment scale to evaluate their results; therefore we could not compare our results in terms of scar assessment scale, as the same with the pain scale during suture removal. However, in our study, we have found near-equal rates of erythema and milia, but the differences are in the time it takes to perform each procedure, in which the continuous technique takes less time than subcuticular technique and the surgeons find it easier to perform.

Tissue reacts differently to different types of suture materials, natural materials tend to cause more tissue reaction and erythema, since we used synthetic monofilament non-absorbable material, we did not experience much erythema and tissue reaction except in one patient in each group which most of the erythema resolved by the end of the first-week postoperatively^(7,15).

As regards the limitation of our study, the main restriction was the limited number of patients as the patients were presenting to our center were quite a few and we had limited time to finish the study. Another limitation is the difference in the dermatological character of the patients, specific results would have been obtained if we used both techniques on the same patient with one for each eye. In the future, it would be more informative and more specific if we conduct a clinical trial on the larger number of patients and using

of both techniques on the same patient to overcome the mentioned limitations above.

In conclusion; we did not find a significant difference in the complications and the outcome between the aforementioned methods of eyelid wound closure, the selection of the procedure is up to the surgeon, we do not recommend the surgeons to change their method of closure, we provide our findings for consideration and further study.

REFERENCES

1. Ilankovan V. Aesthetic blepharoplasty. *Br J Oral Maxillofac Surg.* 2010;48(7):493-7.
2. Hoorntje LE, Lei B van der, Stollenwerck GA, Kon M. Resecting orbicularis oculi muscle in upper eyelid blepharoplasty - A review of the literature. *J Plast Reconstr Aesthetic Surg.* 2010;63(5):787-92.
3. Bassichis BA. Cosmetic upper-lid blepharoplasty. *Oper Tech Otolaryngol - Head Neck Surg.* 2007;18(3):203-8.
4. Rohrich RJ, Coberly DM, Fagien S, Stuzin JM. Current concepts in aesthetic upper blepharoplasty. *Plast Reconstr Surg.* 2004;113(3):32e-42e.
5. Lam SM, Asian blepharoplasty. *Pearls Pitfalls Cosmet Oculoplastic Surgery*, 2nd edition. New York: Springer New York; 2015. P. 127-129.
6. Joshi AS, Janjanin S, Tanna N, Geist C, Lindsey C. Does suture material and technique matter? Lessons learned from 800 consecutive blepharoplasties. *Laryngoscope.* 2007;117(6):981-4.
7. Guyuron B, Vaughan C. A Comparison of Absorbable and Nonabsorbable Suture Materials for Skin Repair. *Plast Reconstr Surg.* 1992;89(2) 234-6.
8. Patrocinio TG, Loredó BAS, Arevalo CEA, Gómespatrocinio L, Patrocinio JA. Complications in blepharoplasty: How to avoid and manage them. *Braz J Otorhinolaryngol.* 2011;77(3):322-7.
9. Lew H, Goldberg RA. Maximizing Symmetry in Upper Blepharoplasty: The Role of Microptosis Surgery. *Plast Reconstr Surg.* 2016;137(2):296e-304e.
10. Codner MA, Burke RM. Blepharoplasty. *Grabb and Smith's Plastic Surgery*. 7th edition. Philadelphia: Wolters Kluwer; 2014. P. 487-500.
11. Draaijers LJ, Tempelman FRH, Botman YAM, Tuinebreijer WE, Middelkoop E, Kreis RW, et al. The patient and observer scar assessment scale: a reliable and feasible tool for scar evaluation. *Plast Reconstr Surg.* 2004;113(7):1960-5.
12. Suriano MM, Stirbu O, Pérez M D, Serra Segarra M. Blepharoplasty: to suture or to use cyanoacrylate? *Arch Soc Esp Oftalmol.* 2011;86(3):81-4.
13. Wu LW, Ye Z, Xu Y, Yu J, Wu Y. Orbicularis-levator-tarsus composite suture technique in double-eyelid operation. *J Plast Reconstr Aesthetic Surg.* 2015;68(8):1079-84.
14. Fagien S. The role of the orbicularis oculi muscle and the eyelid crease in optimizing results in aesthetic upper blepharoplasty: A new look at the surgical treatment of mild upper eyelid fissure and fold asymmetries. *Plast Reconstr Surg.* 2010;125(2):653-66.
15. Scaccia FJ, Hoffman JA, Stepnick DW. Upper Eyelid Blepharoplasty: A Technical Comparative Analysis. *JAMA Otolaryngol Neck Surg.* 1994 Aug 1;120(8):827-30.